

Dartmouth College

Dartmouth Digital Commons

Open Dartmouth: Published works by
Dartmouth faculty

Faculty Work

8-2005

Experimental Ocular Toxoplasmosis in Genetically Susceptible and Resistant Mice

Fangli Lu

Dartmouth College

Shiguang Huang

Dartmouth College

Mark S. Hu

Dartmouth College

Lloyd H. Kasper

Dartmouth College

Follow this and additional works at: <https://digitalcommons.dartmouth.edu/facoa>



Part of the [Infectious Disease Commons](#), [Medical Immunology Commons](#), and the [Medical Microbiology Commons](#)

Dartmouth Digital Commons Citation

Lu, Fangli; Huang, Shiguang; Hu, Mark S.; and Kasper, Lloyd H., "Experimental Ocular Toxoplasmosis in Genetically Susceptible and Resistant Mice" (2005). *Open Dartmouth: Published works by Dartmouth faculty*. 951.

<https://digitalcommons.dartmouth.edu/facoa/951>

This Article is brought to you for free and open access by the Faculty Work at Dartmouth Digital Commons. It has been accepted for inclusion in Open Dartmouth: Published works by Dartmouth faculty by an authorized administrator of Dartmouth Digital Commons. For more information, please contact dartmouthdigitalcommons@groups.dartmouth.edu.

Experimental Ocular Toxoplasmosis in Genetically Susceptible and Resistant Mice

Fangli Lu,[†] Shiguang Huang,[‡] Mark S. Hu,[§] and Lloyd H. Kasper*

Department of Medicine and Microbiology/Immunology, Dartmouth Medical School, Lebanon, New Hampshire 03756

Received 11 February 2005/Accepted 25 March 2005

Genetic factors determining the pathogenesis and course of ocular toxoplasmosis are poorly understood. In this study, we explored the development of experimental ocular pathogenesis in genetically dissimilar mice infected with either the RH strain, the PLK strain, or the immunodominant surface antigen 1 (SAG1 [P30])-deficient mutant of the RH strain of *Toxoplasma gondii*. At 11 days postinfection, ocular infection of C57BL/6 mice with all of the strains of parasites resulted in severe inflammatory lesions and high numbers of parasites in eye tissue; less severe ocular lesions at earlier histopathology and prolonged survival were observed in this mouse strain infected with either the major surface antigen 1-deficient SAG1^{-/-} strain or the less virulent PLK strain compared with RH infection. In contrast, both BALB/c and CBA/J mice had less severe lesions and low numbers of parasites in their eye tissue, and infection developed into the chronic stage in these mice. There were significantly higher serum levels of gamma interferon and tumor necrosis factor alpha in C57BL/6 mice than in BALB/c and CBA/J mice following ocular infection. These observations confirm earlier reports on systemic immunity to these parasites that the route of *Toxoplasma* infection markedly influences survival of mice. Our data indicate that genetic factors of the host as well as the parasite strain are critical in determining susceptibility to experimental ocular toxoplasmosis in murine models.

Toxoplasmosis is a common parasitic zoonosis and an important cause of spontaneous abortion, mental retardation, encephalitis, blindness, and death worldwide (13). Nearly a billion people are infected with *Toxoplasma gondii*, and ocular lesions occur in up to 25% of infected individuals (28). It is widely accepted that there is a significant difference in susceptibility to chronic infection by *T. gondii* among inbred mouse strains with different genetic backgrounds. Host genetics are likely to be important in determining susceptibility to and severity of *T. gondii* infection, as shown by variable disease patterns in inbred mice upon infection (19, 29). Host genes both within and outside the major histocompatibility complex are involved in the impaired intracerebral immune response of C57BL/6 mice (1, 4). The parasite strain is also critical in host genetic regulation of resistance against acute toxoplasmosis (27). Genetic resistance/susceptibility to ocular toxoplasmosis has not been previously studied in mice. Whether such differences in parasite virulence are associated with differing incidences or clinical manifestations of ocular toxoplasmosis remains to be determined. The present study compared the effects of the low-virulence *T. gondii* strain PLK, the high-virulence strain RH, and the surface antigen 1-deficient (SAG1^{-/-} or P30^{-/-}) mutant of RH on the susceptibility of

inbred strains of C57BL/6, BALB/c, and CBA/J mice to acquire acute ocular infection.

MATERIALS AND METHODS

Parasites. The temperature-sensitive mutant strain of *T. gondii* (strain ts-4; kindly provided by Elmer R. Pfefferkorn, Dartmouth Medical School) was used for intraperitoneal (i.p.) vaccination. For primary and challenge infections, *T. gondii* RH tachyzoites, PLK (clonally derived from ME49) tachyzoites, surface antigen 1 knockout (SAG1^{-/-} or P30^{-/-}) RH tachyzoites, and RH tachyzoites engineered to constitutively express green fluorescent protein (RH-GFP) were used. They were maintained by continuous passage in human fibroblasts grown in Dulbecco's modified Eagle medium (Gibco, Grand Island, N.Y.) supplemented with 10% newborn calf serum plus antibiotics.

Mice. Female age-matched (7- to 8-week) C57BL/6, BALB/c, and CBA/J mice were obtained from the Jackson Laboratory. Animals were bred under approved conditions at the animal research facility at Dartmouth Medical School.

Immunization, infection, and challenge. Mice were immunized by i.p. injection of 1×10^5 ts-4 tachyzoites and challenged by eye inoculation of 100 RH, SAG1^{-/-}, or PLK tachyzoites at 45 days postimmunization. Primary infection of naive mice was performed by ocular inoculation with 100 tachyzoites. In some experiments, mice were infected or challenged with 100 RH-GFP tachyzoites. Eye inoculation was performed as previously described (16). In brief, following leakage of aqueous fluid from the right eye after anesthesia, 5 μ l of parasite suspension in Dulbecco's modified Eagle medium was injected into the anterior chamber of the eye by using an operating microscope.

Histopathology and parasite proliferation. At 5, 8, 11, 26, 56, or 85 days postinfection or postchallenge, mice were sacrificed by CO₂ asphyxiation. Eyes were harvested and immediately fixed in 10% buffered formaldehyde (Polysciences, Warrington, Pa.). Five-micrometer-thick sections (50- or 100- μ m distance between sections) of the eyes from each mouse, stained with hematoxylin and eosin (H&E), were evaluated for inflammatory changes. Ocular pathology was scored as follows: 0, normal histology; 1, mild inflammation without necrosis; 2, obvious inflammation without necrosis; 3, strong inflammation with necrosis; 4, whole eye section with prominent necrosis (16).

Confocal laser scanning microscopy. Five-micrometer-thick sections (50- or 100- μ m distance between sections) of the eyes from mice infected or challenged with 100 RH-GFP tachyzoites at day 11 were examined using a Bio-Rad MRC-1024 confocal scanning laser microscope (Bio-Rad, Hercules, Calif.).

Immunohistology. Four-micrometer-thick sections of paraffin wax-embedded eye tissue from mice infected or challenged with 100 RH tachyzoites at day 11 were attached to slides for immunohistology study. Assays were performed using

* Corresponding author. Mailing address: Department of Medicine and Microbiology, Dartmouth Medical School, Ruben Building 7, Lebanon, NH 03756. Phone: (603) 653-9909. Fax: (603) 653-9949. E-mail: Lloyd.H.Kasper@Dartmouth.Edu.

[†] Present address: Laboratory of Malaria and Vector Research, National Institute of Allergy and Infectious Diseases, National Institutes of Health, Rockville, MD 20850.

[‡] Present address: Jinan University School of Medicine, Guangzhou 510632, China.

[§] Present address: Eye Hospital, China Academy of Chinese Medicine, Beijing 100040, China.

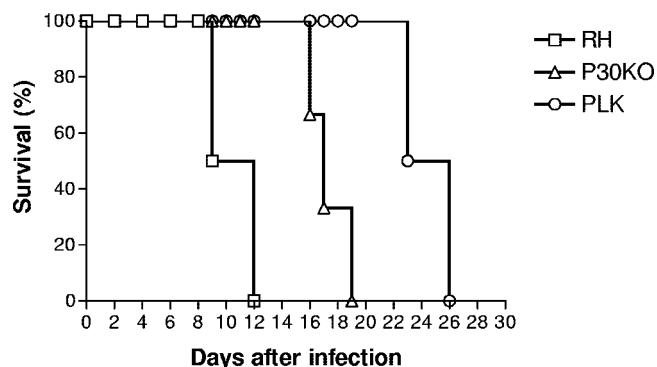


FIG. 1. Mortality in C57BL/6 mice following ocular infection with 100 RH (□), SAG1^{-/-} (△), or PLK (○) tachyzoites of *T. gondii*. There were six mice per group, and data are representative of those from two similar experiments.

a ready-to-use reagent kit (BioGenex, San Ramon, Calif.) according to the manufacturer's instructions. Sections were stained with anti-CD3 monoclonal antibodies (BioGenex).

Levels of IFN-γ and TNF-α in serum and of antitoxoplasma antibody in serum and aqueous fluid. Mice were bled at 11 days postinfection or postchallenge, and sera were collected. Approximately 10 to 15 μl of aqueous fluid was withdrawn using a 27 1/2-gauge needle via a limbal paracentesis from naive mice and mice i.p. immunized with ts-4 at 32 days. The sera and fluids were stored at -70°C until use. Serum levels of gamma interferon (IFN-γ) and tumor necrosis factor alpha (TNF-α) were quantitated with enzyme-linked immunosorbent assay kits (Biosource, Camarillo, Calif.) according to the manufacturer's instructions. Optical densities (ODs) were measured at 450 nm and serum cytokine concentrations determined from the standard curve. Serum and eye fluid levels of anti-*Toxoplasma* immunoglobulin (IgG) were assayed by enzyme-linked immunosorbent assay as previously described (18). Purified RH parasites (5 × 10⁴/well) were placed in microtiter plates, dried overnight, and blocked with 5% bovine serum albumin-phosphate-buffered saline. Antisera and aqueous fluids were incubated at 37°C for 2 h. Plates were washed in 0.05% Tween 20 and supplemented with a peroxidase-conjugated rabbit anti-mouse IgG (Sigma, St. Louis, Mo.) for 1 h. ODs were measured at 450 nm with an automatic microplate reader.

Statistical analysis. Data were analyzed by the Student *t* test or the Wilcoxon signed rank test. *P* values of less than 0.05 were considered statistically significant.

RESULTS

C57BL/6 mice have more severe inflammatory lesions and higher parasite burdens in eye tissue following infection. All C57BL/6 mice infected intracamerally with 100 tachyzoites of RH, SAG1^{-/-}, or PLK *T. gondii* were susceptible to acute ocular infection and died. As shown in Fig. 1, C57BL/6 mice died between days 9 and 12 following RH infection, between days 16 and 19 following SAG1^{-/-} infection (*P* = 0.0002), and between days 23 and 26 following PLK infection (*P* = 0.0001). As shown in Table 1, compared with RH infection, the inflammation and necrosis in the eye tissues of C57BL/6 mice induced by PLK and SAG1^{-/-} were significantly less severe at day 5 postinfection (*P* = 0.028). At day 8 postinfection, the lesions in the eye tissue caused by SAG1^{-/-} reached a severe level similar to that caused by RH; however, the ocular lesion caused by PLK was still significantly less severe at this time point (*P* = 0.043). At day 11 postinfection, similar severe necrosis and inflammation were observed in the eye tissues with infections induced by all strains of parasites (Table 1; Fig. 2A).

TABLE 1. Comparison of inflammatory scores in the eyes of C57BL/6, BALB/c, and CBA/J mice following primary infection with *T. gondii*

Mice	Parasites	Inflammatory score at postinfection day ^a :					
		5	8	11	26	56	85
C57BL/6	RH	2	3	3	— ^b	—	—
		2	3	3			
		2	2	4			
		3	3	3			
		2	3	2			
		3	2	3			
	SAG1 ^{-/-}	2	2	3	—	—	—
		2	3	2			
		1	3	3			
		1	2	3			
		1	3	3			
		1	2	3			
PLK	1	2	3	—	—	—	
	1	2	3				
	1	1	3				
	1	2	3				
	1	2	3				
	1	2	2				
BALB/c	RH	—	—	2	1	1	0.5
				1	1	1	0.5
				2	1	1	0.5
				3	1	0.5	0
				2	2	0.5	1
				2	2	1	0.5
CBA/J	RH	—	—	2	1	0	0.5
				1	1	1	0.5
				2	2	1	0.5
				2	1	0.5	0.5
				3	1	0.5	0
				2	1	0.5	0.5

^a Mice were infected intracamerally with 100 tachyzoites of *T. gondii*, and the inflammatory scores in their eyes were examined at serial time points postinfection. There were six mice in each group (see the text for the details of this experiment). Compared with the infection with RH in C57BL/6 mice, the inflammatory scores in the eye tissues were significantly lower at day 5 postinfection with PLK (*P* = 0.028) and SAG1^{-/-} (*P* = 0.028) and at day 8 postinfection with PLK (*P* = 0.043). In contrast, there were significantly lower inflammatory scores in the eye tissues of both BALB/c and CBA/J mice at day 11 postinfection with RH (*P* = 0.028), and the scores gradually became even lower at days 26 (*P* = 0.043), 56 (*P* = 0.028), and 85 (*P* = 0.028) postinfection.

^b —, not applicable.

BALB/c and CBA/J mice have less severe inflammatory lesions and lower parasite burden in eye tissue following infection. All BALB/c and CBA/J mice were resistant and were in generally good condition throughout the experiment. These mice survived for more than 100 days after ocular infection with all strains of parasites. The features of ocular inflammatory response in BALB/c and CBA/J mice ranged from minimal damage to medium-level destruction of eye tissue. In general, eye tissue lesions of these mice were much less severe at 11 days postinfection (Table 1; Fig. 2C and 2E). The inflammation scores in the eye tissues of both BALB/c and CBA/J mice were the highest at day 11 postinfection with the RH strain; the degree of inflammation and necrosis gradually became less severe at days 26 (*P* = 0.043), 56 (*P* = 0.028), and 85

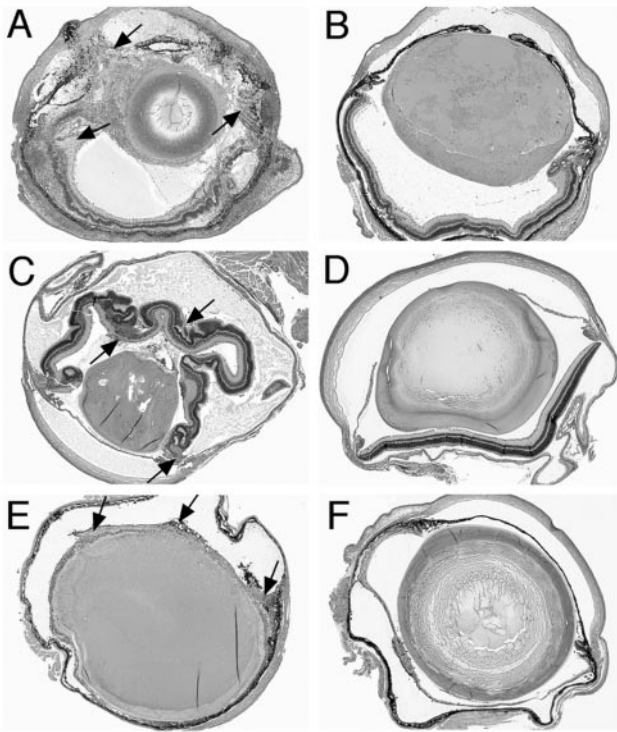


FIG. 2. Pathology of mouse eyes at 11 days after ocular infection with 100 RH tachyzoites of *T. gondii*. Panels: infected (A) and challenged (B) C57BL/6 mouse, infected (C) and challenged (D) BALB/c mouse, and infected (E) and challenged (F) CBA/J mouse. There were six mice per group, and data are representative of those from two experiments. Arrows indicate necrosis or inflammation. Magnification, $\times 4$; H&E stain.

($P = 0.028$) postinfection. There were no significant differences in ocular lesions among the parasite strain infections between BALB/c and CBA/J mice at the serial time points (data not shown). Observation by confocal microscopy showed that the numbers of RH-GFP tachyzoites in the eye tissue of C57BL/6 mice (Fig. 3A) were markedly higher than those in BALB/c mice (Fig. 3B) at day 11 postinfection with 100 RH-GFP. The numbers of parasites in the eye tissue of CBA/J mice were similar to those in BALB/c mice (data not shown).

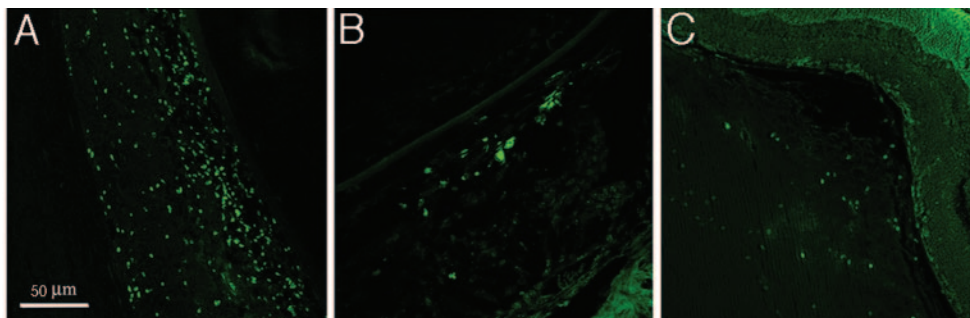


FIG. 3. Parasites with green fluorescence in the eye tissue of mice at 11 days postinfection or postchallenge with 100 RH-GFP tachyzoites of *T. gondii*. Panels: infected C57BL/6 mouse (A), infected BALB/c mouse (B), and challenged C57BL/6 mouse (C). There were six mice per group, and data are representative of those from two experiments.

All strains of vaccinated mice show nearly complete protection following challenge. When mice were immunized i.p. with ts-4 and challenged with 100 RH, PLK, or SAG1^{-/-} tachyzoites by the ocular route, either no evidence of necrosis or only mild inflammation was observed in the eye tissue from C57BL/6, BALB/c, and CBA/J mice (Fig. 2B, 2D, and 2F). There were no significant differences in ocular histopathology either among the strains of mice or among challenges with parasite strains. There were much lower numbers of parasites in the challenged eyes (Fig. 3C) than in the infected eyes (Fig. 3A) in C57BL/6 mice at day 11 postinoculation with 100 RH-GFP tachyzoites.

T cells in the eye tissue of challenged mice. Because there was almost complete protection in the eyes of challenged mice, immunohistologic studies were performed to determine the effector cells in the eyes. The results showed that the major effectors in the eye tissue of challenged C57BL/6 mice were lymphocytes, in which CD3⁺ T cells were the main response cells (Fig. 4).

Serum levels of IFN- γ and TNF- α and antitoxoplasma antibody levels in serum and aqueous fluid. Compared with day 0, there were significant increases of serum levels of IFN- γ and TNF- α in all strains of mice at 11 days after either primary ocular infection with RH ($P < 0.01$) or ts-4 vaccination and challenge with RH ($P < 0.05$); however, there were significantly higher serum levels of IFN- γ ($P < 0.01$) and TNF- α ($P < 0.01$) in C57BL/6 mice than in BALB/c and CBA/J mice following ocular infection (Fig. 5). The serum levels of IFN- γ and TNF- α were not significantly different among the infections with the RH, SAG1^{-/-}, and PLK strains of *T. gondii* at day 11 (data not shown). The serum IgG level (OD) was significantly increased in all strains of mice at 11 days after both infection ($P < 0.05$) and challenge ($P < 0.01$) (Fig. 6, top); the IgG level in the eye fluids from all strains of mice were significantly increased after i.p. immunization with ts-4 ($P < 0.01$) (Fig. 6, bottom).

DISCUSSION

Following ocular infection with tachyzoites of the high-virulence *T. gondii* RH strain, the low-virulence PLK strain, and the SAG1^{-/-} mutant of the RH strain, all strains of inbred mice developed ocular toxoplasmosis; however, the intraocular

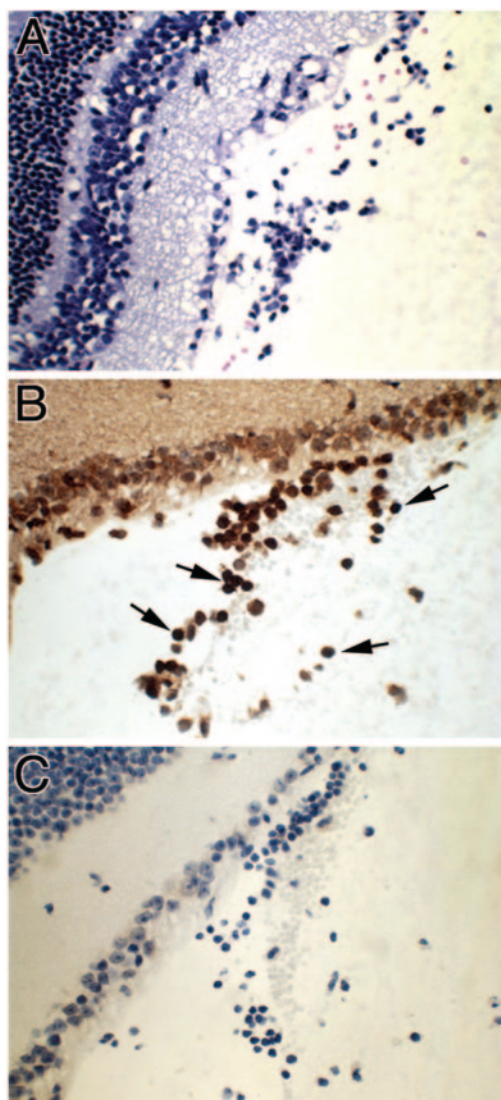


FIG. 4. Eye tissue from a control mouse challenged with 100 RH tachyzoites of *T. gondii* at 11 days. Shown is the eye with H&E staining (A), immunohistology with anti-CD3 monoclonal antibody staining (B), and immunohistology of a negative control (C). Four mice were used in each group; this experiment is representative of two performed. Arrows indicate CD3-positive cells. Magnification, $\times 10$.

immune responses were significantly different among the strains of mice and strains of *Toxoplasma*. We observed that C57BL/6 mice were highly susceptible to ocular infection with *T. gondii*. These mice developed a syndrome with a severely necrotizing and fatal ocular toxoplasmosis and a mortality rate of 100% between 9 and 12 days after ocular infection with the RH strain of *T. gondii*. In contrast, BALB/c and CBA/J mice were resistant to ocular *Toxoplasma* infection and had more protracted, less severe necrosis and inflammation in their eye tissues. With 100% survival at day 12 postinfection, most could survive for more than 100 days postinfection. From days 26, 56, and 85 postinfection, the lesions in eye tissues of BALB/c and CBA/J mice became gradually less severe. We also observed that C57BL/6 mice had high numbers of tachyzoites in the eye tissue, whereas BALB/c and CBA/J mice had much lower

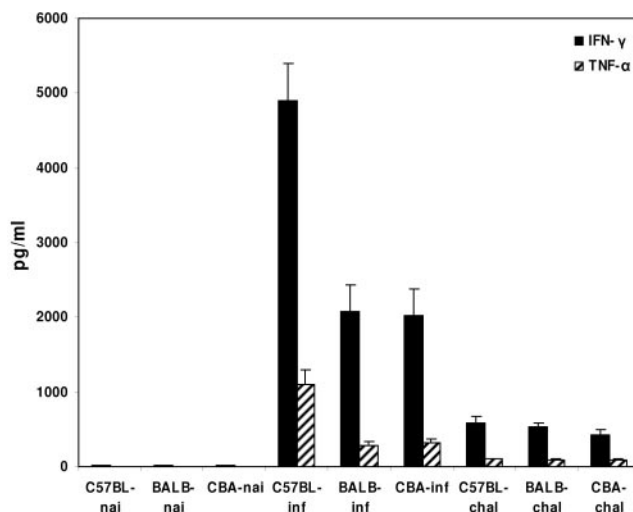


FIG. 5. Serum levels of IFN- γ and TNF- α . Experiments were performed on C57BL/6, BALB/c, and CBA/J mice infected or challenged intracamerally with 100 RH tachyzoites of *T. gondii* at 11 days. Four mice were used in each group, and data shown are pooled from two separate experiments. Error bars indicate standard deviations.

numbers of parasites in their eye tissues at 11 days postinfection. Norose et al. (21) observed that cysts proliferate at a higher rate and are in much higher numbers in the eye tissues of C57BL/6 mice than in those of BALB/c mice following peroral infection with the Fukaya strain of *T. gondii*. Luo et al. (17) reported that the numbers of *T. gondii* in brain are greatly increased in C57BL/6 mice but not in BALB/c mice at 2 weeks following infection. These findings indicate that genetically determined host factors are involved in the course of ocular toxoplasmosis in murine models.

It has been reported that the RH strain of *T. gondii* is highly virulent in all mouse strains, with a 100% lethal dose of <10 parasites (22). However, we observed that, compared with C57BL/6 mice, BALB/c and CBA/J mice infected with 100 RH strain organisms through the ocular route not only experienced less severe ocular pathology but also survived throughout the experimental window of 100 days postinfection. Murine susceptibility to *T. gondii* or resistance to mortality following acute peroral infection with *T. gondii* is under multigenic control (18, 29); the pathogenicity of *T. gondii* can be influenced by the route of inoculation, by the genotypes of the host and parasite, and by the life cycle stage of the parasite (9, 18, 25, 26). The route of infection of *Toxoplasma* markedly influences survival of mice (9, 10). Genetic factors are determinants of susceptibility to toxoplasmosis; e.g., B10 mice are highly susceptible to *Toxoplasma* encephalitis and C57BL/6 mice are susceptible to oral or i.p. infection with *T. gondii*, while BALB/c mice are resistant to infection by either route (4, 9). Besides a higher parasite burden in the eye tissue, C57BL/6 mice also developed systemic toxoplasmosis and destructive inflammation in multiple organs following infection, but BALB/c and CBA/J mice did not (data not shown). It has been reported that survival of mice during the acute stage of *T. gondii* infection is influenced by major histocompatibility complex class II genes *Ia* and *Ie* (10). Although the factors that control *Toxoplasma* disease

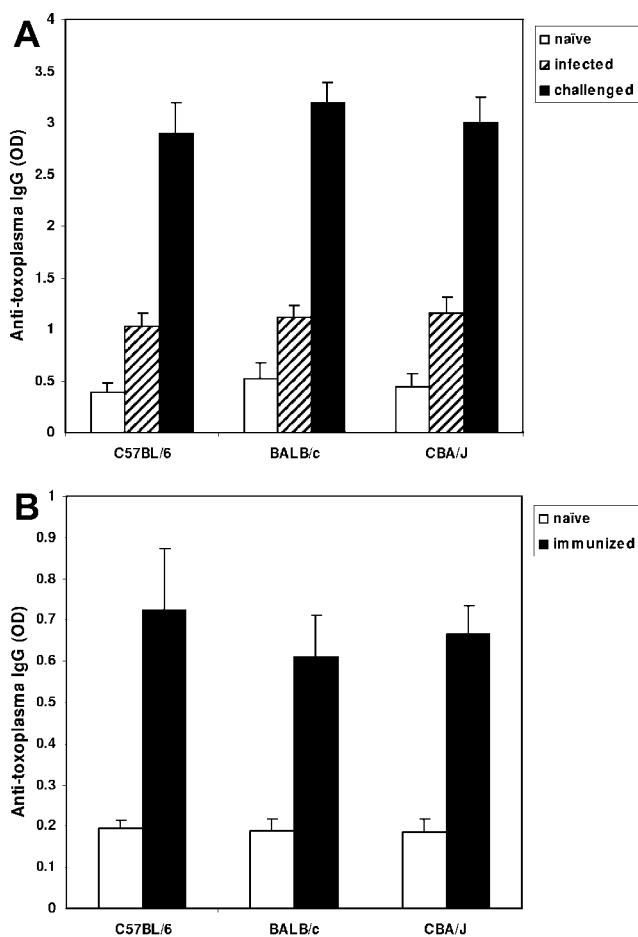


FIG. 6. (Top) Serum anti-*Toxoplasma* IgG levels. Experiments were performed on mice infected or challenged intracamerally with 100 *T. gondii* RH tachyzoites at 11 days. (Bottom) Anti-*Toxoplasma* IgG levels in eye fluid. Samples were collected from mice i.p. vaccinated with *T. gondii* ts-4 at 32 days. Four mice were used in each group, and data shown are pooled from two separate experiments. Error bars indicate standard deviations.

severity are not well understood, our findings further support that the specific route of infection, such as the ocular route used in this study, is an important influence.

We observed that C57BL/6 mice infected with the *T. gondii* high-virulence RH strain, its SAG1^{-/-} mutant, and the low-virulence PLK strain had significantly different outcomes in acute ocular infection. Infection with RH led to rapid death with severe ocular lesions in C57BL/6 mice, whereas infection with PLK or SAG1^{-/-} markedly delayed death. The lesions in eye tissues were much less severe at days 5 and 8 postinfection with PLK and at day 5 postinfection with SAG1^{-/-}, although the degree of ocular lesion reached the same severe level at day 11 postinfection. All of the mice eventually died of acute ocular toxoplasmosis from 9 to 26 days after infection. Howe and Sibley (7) reported that the type I lineage of *T. gondii*, typified by the RH strain, has higher virulence in mice; type II (e.g., ME49) and type III strains have lower virulence in mice. Genetic control of resistance against acute infection with *T. gondii* differs depending on the strain of *T. gondii* (27). Gavrilescu and Denkers (5) demonstrated that there are sig-

nificant differences in the immunity induced by high- and low-virulence strains of *T. gondii* and that in C57BL/6 mice infected with RH, tachyzoite dissemination of infection is more widespread and parasite levels are dramatically higher than in those infected with ME49. Our data reveal that the parasite strain itself plays an important role in determining the outcome of ocular toxoplasmosis in mice. It has been demonstrated that SAG1 is involved in parasite attachment and invasion (6, 20). SAG1 peptides are expressed on the surface of the infected macrophages and can be recognized by antibody- and antigen-specific immune effector T cells (11). SAG1 is also highly immunogenic, and humoral and cellular responses of the host against this protein are capable of limiting acute infection by clearing *Toxoplasma* tachyzoites (2, 12). The importance of this parasite molecule in ocular infection has not been reported. In this study, the decreased ocular lesion at early-stage infection and the prolonged survival of C57BL/6 mice infected with the SAG1^{-/-} mutant of RH indicate that SAG1 is associated with the virulence and pathogenesis of the RH strain of *T. gondii*.

The pathogenic mechanisms in ocular toxoplasmosis, including invasion and parasitization of eye tissues by the *Toxoplasma* parasite and localized tissue damage by a complex associated immune response (8, 15), are not well understood. Our previous studies have revealed that the ocular pathogenesis is initially due to parasite invasion and proliferation and influences of the immune response (15). CD4⁺ T cells are the major source of production of IFN- γ and TNF- α and are essential to the pathogenesis of ocular toxoplasmosis (16). In this study, we observed that the ocular pathogenesis in C57BL/6 mice was much severe than that in BALB/c and CBA/J mice and that the serum levels of IFN- γ and TNF- α in C57BL/6 mice were significantly higher than those in BALB/c and CBA/J mice following ocular infection with *T. gondii*. Norose et al. (21) observed that there are higher levels of IFN- γ mRNA expression in the retinas of C57BL/6 mice than in those of BALB/c mice infected with the Fukaya strain of *T. gondii*. IFN- γ mediates immunopathology and contributes to early death following RH *T. gondii* infection (14); a decline in IFN- γ production in CD4-deficient mice protects mice from mortality due to a hyperimmune response (3). IFN- γ has been shown to regulate the *T. gondii* load and interconversion in the murine eye (21). TNF- α plays an important role in resistance to acute and chronic toxoplasmosis; however, the extremely high levels of this cytokine produced during lethal infection can potentially contribute to pathogenesis (24). Compared with RH infection of C57BL/6 mice, these mice infected with SAG1^{-/-} or PLK survived longer, but there were no significant differences in these cytokine levels in serum at day 11 after ocular infection, suggesting that these cytokines are not the sole factor influencing mouse survival. Our data indicate that genetically determined host factors are involved in the ocular immune response: C57BL/6 mice are susceptible, while BALB/c and CBA/J mice are resistant, to ocular infection with the RH strain of *T. gondii*.

Compared with those in infected mice, fewer parasites in the challenged eye tissues and nearly complete protection were observed in either C57BL/6, BALB/c, or CBA/J mice vaccinated i.p. with ts-4 following ocular challenge, suggesting that the ts-4 strain of *T. gondii* is an effective vaccine for prevention of ocular toxoplasmosis induced by high- and low-virulence

strains of *T. gondii* in all strains of mice. We observed increased serum levels of IFN- γ , TNF- α , and anti-*Toxoplasma* IgG in challenged mice and increased IgG levels in eye fluid from mice i.p. immunized with ts-4. ts-4 elicits a strong IFN- γ -dependent immune response (23). Our data indicate that the high levels of IFN- γ and TNF- α play a protective role against *T. gondii*. Our previous studies demonstrated that CD8⁺ T-cell immunity is essential for the survival of ts-4 immunization and RH challenge and that B cells are required to produce antibodies which control parasite replication for resistance to *T. gondii* after both infection and challenge (16). In this study, CD3⁺ T cells were found to be the major response cells in the eyes of challenged mice, which suggest that the positive CD3⁺ T cells in the eye tissue of challenged mice may be CD3⁺ CD8⁺ T cells.

In conclusion, our findings are helpful in understanding the complex mechanisms of both the host and parasite that induce pathogenesis of ocular toxoplasmosis.

ACKNOWLEDGMENTS

We thank Joseph D. Schwartzman for histologic analysis, Kenneth A. Orndorff for excellent technical assistance with confocal scanning laser microscopy, and Maudine D. Waterman for immunohistological staining. We are grateful to Michael E. Grigg and John C. Boothroyd for providing SAG1^{-/-} and RH-GFP parasites and to Chitali Dutta and Sakhina Haque-Begum for providing valuable technical information. We thank Nancy Shulman for editorial assistance.

This work was supported by grants A119613, A130000, and TW01003 from the National Institutes of Health.

REFERENCES

- Brown, C. R., and R. McLeod. 1990. Class I MHC genes and CD8⁺ T cells determine cyst number in *Toxoplasma gondii* infection. *J. Immunol.* **145**: 3438–3441.
- Bulow, R., and J. C. Boothroyd. 1991. Protection of mice from fatal *Toxoplasma gondii* infection by immunization with p30 antigen in liposomes. *J. Immunol.* **147**:3496–3500.
- Casciotti, L., K. H. Ely, M. E. Williams, and I. A. Khan. 2002. CD8⁺ T-cell immunity against *Toxoplasma gondii* can be induced but not maintained in mice lacking conventional CD4⁺ T cells. *Infect. Immun.* **70**:434–443.
- Deckert-Schluter, M., D. Schluter, D. Schmidt, G. Schwendemann, O. D. Wiestler, and H. Hof. 1994. *Toxoplasma* encephalitis in congenic B10 and BALB mice: impact of genetic factors on the immune response. *Infect. Immun.* **62**:221–228.
- Gavrilescu, L. C., and E. Y. Denkers. 2001. IFN- γ overproduction and high level of apoptosis are associated with high but not low virulence *Toxoplasma gondii* infection. *J. Immunol.* **167**:902–909.
- Grimwood, J., and J. E. Smith. 1996. *Toxoplasma gondii*: the role of parasite surface and secreted proteins in host cell invasion. *Int. J. Parasitol.* **26**:169–173.
- Howe, D. K., and L. D. Sibley. 1995. *Toxoplasma gondii* comprises three clonal lineages: correlation of parasite genotype with human diseases. *J. Infect. Dis.* **172**:1561–1566.
- Hu, M. S., J. D. Schwartzman, A. C. Lepage, I. A. Khan, and L. H. Kasper. 1999. Experimental ocular toxoplasmosis induced in naïve and preinfected mice by intracameral inoculation. *Ocul. Immunol. Inflamm.* **7**:17–26.
- Johnson, A. M. 1984. Strain-dependent, route-of-challenge-dependent, murine susceptibility to toxoplasmosis. *Z. Parasitenkd.* **70**:303–309.
- Johnson, J., Y. Suzuki, D. Mack, E. Mui, R. Estes, C. David, E. Skamene, J. Forman, and R. McLeod. 2002. Genetic analysis of influences on survival following *Toxoplasma gondii* infection. *Int. J. Parasitol.* **32**:179–185.
- Kasper, L. H., I. A. Khan, K. H. Ely, R. Buelow, and J. C. Boothroyd. 1992. Antigen-specific (p30) mouse CD8⁺ T cells are cytotoxic against *Toxoplasma gondii*-infected peritoneal macrophages. *J. Immunol.* **148**:1493–1498.
- Khan, I. A., K. H. Ely, and L. H. Kasper. 1991. A purified parasite antigen (p30) mediates CD8⁺ T cell immunity against fatal *Toxoplasma gondii* infection in mice. *J. Immunol.* **147**:3501–3506.
- Klaren, V. N., and A. Kijlstra. 2002. Toxoplasmosis, an overview with emphasis on ocular involvement. *Ocul. Immunol. Inflamm.* **10**:1–26.
- Liesenfeld, O., J. Kosek, J. S. Remington, and Y. Suzuki. 1996. Association of CD4⁺ T cell-dependent, IFN- γ -mediated necrosis of the small intestine with genetic susceptibility of mice to peroral infection with *Toxoplasma gondii*. *J. Exp. Med.* **184**:597–609.
- Lu, F., S. Huang, and L. H. Kasper. 2003. Interleukin-10 and pathogenesis of murine ocular toxoplasmosis. *Infect. Immun.* **71**:7159–7163.
- Lu, F., S. Huang, and L. H. Kasper. 2004. CD4⁺ T cells in the pathogenesis of murine ocular toxoplasmosis. *Infect. Immun.* **72**:4966–4972.
- Luo, W., F. Aosai, M. Ueda, K. Yamashita, K. Shimizu, S. Sekiya, and A. Yano. 1997. Kinetics in parasite abundance in susceptible and resistant mice infected with an avirulent strain of *Toxoplasma gondii* by using quantitative competitive PCR. *J. Parasitol.* **83**:1070–1074.
- McLeod, R., P. Eisenhauer, D. Mack, C. Brown, G. Filice, and G. Spitalny. 1989. Immune responses associated with early survival after peroral infection with *Toxoplasma gondii*. *J. Immunol.* **142**:3247–3255.
- McLeod, R., E. Skamene, C. R. Brown, P. B. Eisenhauer, and D. G. Mack. 1989. Genetic regulation of early survival and cyst number after peroral *Toxoplasma gondii* infection of A \times B/B \times A recombinant inbred and B10 congenic mice. *J. Immunol.* **143**:3031–3034.
- Mineo, J. R., R. McLeod, D. Mack, J. Smith, I. A. Khan, K. H. Ely, and L. H. Kasper. 1993. Antibodies to *Toxoplasma gondii* major surface protein (SAG-1, P30) inhibit infection of host cells and are produced in murine intestine after peroral infection. *J. Immunol.* **150**:3951–3964.
- Norose, K., H. S. Mun, F. Aosai, M. Chen, L. X. Piao, M. Kobayashi, Y. Iwakura, and A. Yano. 2003. IFN- γ -regulated *Toxoplasma gondii* distribution and load in the murine eye. *Invest. Ophthalmol. Vis. Sci.* **44**:4375–4381.
- Pfefferkorn, E. R., and L. C. Pfefferkorn. 1976. *Toxoplasma gondii*: isolation and preliminary characterization of temperature-sensitive mutants. *Exp. Parasitol.* **39**:365–376.
- Sayles, P. C., and L. L. Johnson. 1996. Intact immune defenses are required for mice to resist the ts-4 vaccine strain of *Toxoplasma gondii*. *Infect. Immun.* **64**:3088–3092.
- Sibley, L. D., D. G. Mordue, C. Su, P. M. Robben, and D. K. Howe. 2002. Genetic approaches to studying virulence and pathogenesis in *Toxoplasma gondii*. *Philos. Trans. R. Soc. London B* **357**:81–88.
- Suzuki, Y., F. K. Conley, and J. S. Remington. 1989. Differences in virulence and development of encephalitis during chronic infection vary with the strain of *Toxoplasma gondii*. *J. Infect. Dis.* **159**:790–794.
- Suzuki, Y., M. A. Orellana, S. Y. Won, F. K. Conley, and J. S. Remington. 1993. Susceptibility to chronic infection with *Toxoplasma gondii* does not correlate with susceptibility to acute infection in mice. *Infect. Immun.* **61**: 2284–2288.
- Suzuki, Y., Q. Yang, and J. S. Remington. 1995. Genetic resistance against acute toxoplasmosis depends on the strain of *Toxoplasma gondii*. *J. Parasitol.* **81**:1032–1034.
- Vallochi, A., M. Nakamura, D. Schlesinger, M. Martins, C. Silveira, R. Belfort, and L. Rizzo. 2002. Ocular toxoplasmosis: more than just what meets the eye. *Scand. J. Immunol.* **55**:324–328.
- Williams, D. M., F. C. Grumet, and J. S. Remington. 1978. Genetic control of murine resistance to *Toxoplasma gondii*. *Infect. Immun.* **19**:416–420.